

An Emerging Trend of Anaerobes: *Porphyromonas Levii* Causing Necrotic Vulvo Vaginitis. A Case Report

Mubarak Zeb¹, Hina Tariq², Waqar Khan³, Effa Khan¹, Arif Hussain¹, Badar Jehan Farooqi¹, Sikandar Khan Sherwani⁴

¹Department of Microbiology, Dr. Ziauddin University Hospital, North Nazimabad Campus, Karachi, Pakistan.

²Department of Clinical Laboratory Sciences Ziauddin Medical University Karachi, Pakistan.

³Genome Center for Molecular Diagnosis and research Lahore, Pakistan.

⁴Department of Microbiology, Federal Urdu University, Karachi, Pakistan.

Email: mubarkzb@gmail.com

Abstract – *Porphyromonas levii* is a gram negative anaerobic rod. It is non-motile chemoorganotroph bacteria. It was previously included in the genus named *Bacteroides*, but non on molecular basis, 16S rRNA studies it belongs to genus *porphyromonas*. *Porphyromonas levii* also isolated from female vagina also consider as normal vaginal flora. It can cause brain abscess, otitis media, mastoiditis, chronic osteomyelitis and bacterial vaginosis in human. In our case a 13 years old girl was admitted in a tertiary care hospital with yellow foul smelling vaginal discharge, itching, and abdominal pain. After bacterial culture the anaerobic organism is identified as *Porphyromonas levii*. *Porphyromonas levii* have caused Vulvo vaginitis which reflects that rare pathogen can also capable of causing of this disease. This also highlights the importance of culture and sensitivity in management of diseases. In our society the importance of culture and sensitivity should be highlighted, as well as the microbiology laboratory should be standardized, well equipped and well trained staff. *Porphyromonas levii* is an anaerobic bacteria and required strict anaerobic condition and technical skills to be cultivated, this can only be possible if Microbiology laboratory in our community are standardized, and else we would be missing the diagnosis of this emerging pathogen.

Keywords – *Porphyromonas Levii*. Anaerobes. Vaginitis. Vaginoplasty. Fastidious

1. Introduction

Porphyromonas levii is a gram negative anaerobic rod. It is non-motile chemoorganotroph bacteria. It was previously included in the genus named *Bacteroides*, but non on molecular basis, 16S rRNA studies it belongs to genus *porphyromonas* [1, 2]. *Porphyromonas levii* is an emerging human pathogen which is involved in various human infections, such as soft tissue infection, brain abscess, otitis media, mastoiditis, chronic osteomyelitis and bacterial vaginosis [3]-[5].

Porphyromonas levii is also considered as a pathogenic agent in bovin necrotizing Vulvo vaginitis [6]. It also isolated from vagina of women's where it is considered as normal vaginal flora especially in pregnant women but can lead to bacterial vaginosis [7]. *Porphyromonas levii* is equipped with various virulence factors, which assessed it during pathogenesis; the most important one is IgG2 protease. It also decreased chemo taxis and phagocytosis of macrophages [8]-[10].

2. Case Report

14 years old girl was admitted in Ziauddin University Hospital, with history of vaginal discharge. She was unmarried virgin girl and was suffering from discharge for last

one week. She was a-febrile and was not suffering from any other comorbids. According to her she suffered from this disease for the very first time of her life, her menstrual cycle started at the age of 13 years, and last menstrual cycle was two week before her presenting complains, it was normal and lasted for 5 days. On local vaginal examination the vagina was inflamed, the vaginal discharge was yellow in color with foul smelling. The patient did not use any oral or local antibiotic for treatment purpose. Initially for one to two days the vaginal discharge was scanty with mild itching, but for last three days the discharge was increased and symptoms of itch and burning got intense.

She had no urinary symptoms, urine detail report and urine culture showed no evidence of urinary tract infection, her full blood count raveled no significant finding, FBC showed Hb% 10.5 gm/dl, TLC 7.3×10⁹/L and platelet count 299×10⁹/L which is within normal reference ranges.

The vaginal discharge was aseptically collected in sterile container and send immediately to microbiology laboratory for processing. Under sterile condition the sample was inoculated on Chocolate agar, Colistin Nalidixic acid agar and Mac Conkey's agar, sample was also inoculated on Cooked meat medium (Anaerobic Selective medium), a smear on a sterile slide for gram staining was also prepared,

on gram staining it reviewed numerous pus cell with few gram negative diplococci. After inoculation chocolate agar was incubated in 35 °C±25% CO₂ incubator and Colistin Nalidaxic acid agar, Mac Conkey's and Cooked meat broth were incubated at 37 °C± 2 ambient air incubator.

After overnight incubation the agar plates were reviewed and showed no aerobic growth, the cooked meat medium was sub cultured on 5% SBA and was closed in Anaerobic jar along with ATCC *Pseudomonas aeruginosa* 27853 strain as a negative control, the jar was incubated at

37 °C ± 2 incubator for 48 hours.

After the elapsed time the plates were examined, the negative control showed no growth reflecting strict anaerobic condition maintain inside the jar. The Sheep Blood agar and Chocolate agar plates showed circular, entire, low convex, and semi opaque pigmented colonies (Figures 1 & 2), Gram staining was done and it showed gram negative rods. The pigmented bacteria was Catalase negative, for further identification of this gram negative Anaerobic rods was done by using Analytical Profile Index (API) Rapid ID (A-KIT, Figure 4), showed Negative esculin hydrolysis, Alpha-galactosidase, catalase, Alpha-fucosidase and indole, where is positive for N-Acetylcysteine beta-D-glucosaminidase, Beta-galactosidase. On the basis of (API) Rapid ID (A-KIT), reaction the organism was identified as *Porphyromonas levii*.

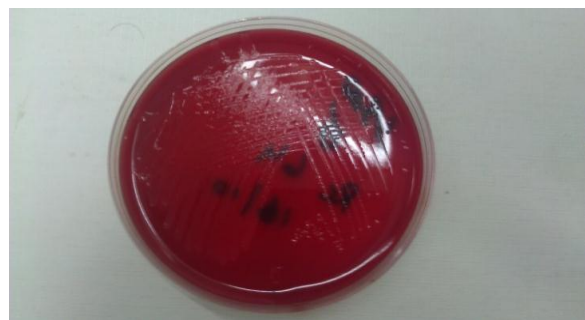


Figure 1. circular, entire, low convex, and semi opaque Colonies on Sheep Blood Agar Medium

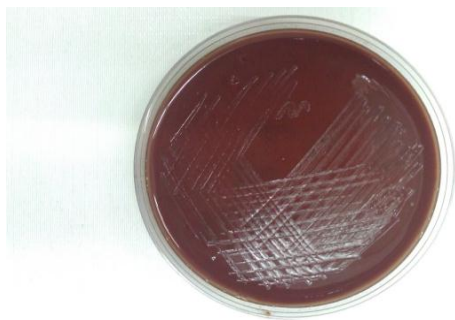


Figure 2. circular, entire, low convex, and semi opaque Colonies on Chocolate Agar Medium

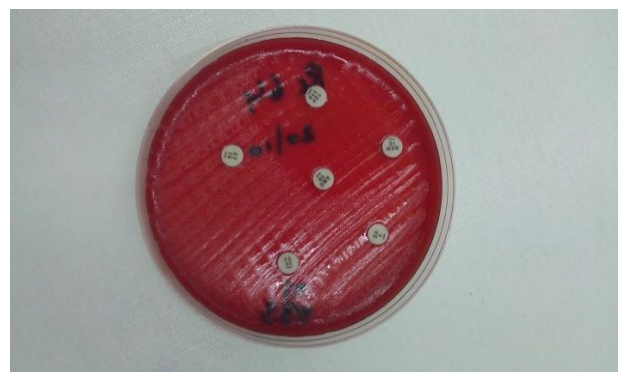

Figure 3. In Vitro Sensitivity Testing of P.levii on Sheep Blood Agar

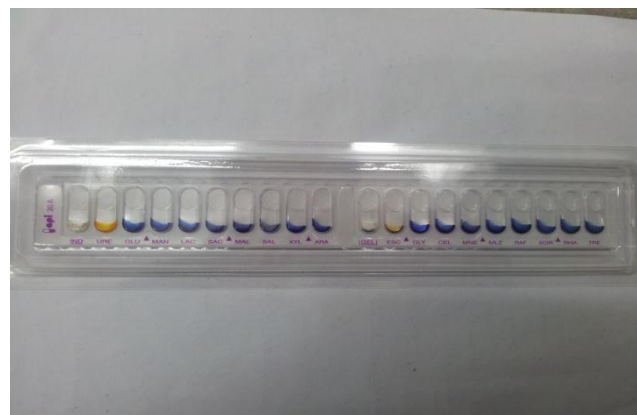


Figure 4. Analytical Profile Index A for the Identification of P.levii

Antibiotics susceptibility testing was done by Kirby-Bauer method, as per NCCLS guidelines, using standard microbiological technique. The organism was susceptible to Amoxicillin-Clavulanic acid, Meropenem, Imipenem, and Tazobactam/Piperacillin, whereas Clindamycin and Metronidazole was resistant (Figure 3). The patient was treated with Amox-Clave 625mg BD for 7 days, and the patient symptoms subside.

3. Discussion

The anaerobic gram negative bacteria *Porphyromonas levii* is an emerging human and animal pathogen. It was previously diagnosed in various human as well as veterinary infections [11]. In Israel during the end of year 2000 various out breaks of bovine necrotic Volvo vaginitis caused by *Porphyromonas levii* has been reported in dairy herds [11].

In our case the patient is a young female who is unmarried and has no past sexual history, and she has no contact with animals, which rules out the zoonotic transmission and sexually transmitted Volvo vaginitis, which commonly caused by yeast named *Candida* species, as well as *Bacteroides species*, *Mobiluncus species*, *Gardenella vaginalis* and parasite name *Trichomonas species* [12]. Usually these organisms are commonly thought as well as

empirically for Vulvo vaginitis infection.

In our case in which the isolated *Porphyromonas levii* have caused Vulvo vaginitis which reflects that rare pathogen can also capable of causing of this disease. This also highlights the importance of culture and sensitivity in management of diseases. *Porphyromonas levii* isolated in this case is resistant to Metronadazole, this antimicrobial agent is commonly used in our society is a therapeutic option for Vulvo vaginitis and so it could lead to therapeutic failure. In our society the importance of culture and sensitivity should be highlighted, as well as the microbiology laboratory should be standardized, well equipped and well trained staff.

Porphyromonas levii is an anaerobic bacteria and required strict anaerobic condition and technical skills to be cultivated, this can only be possible if Microbiology laboratory in our community are standardized, and else we would be missing the diagnosis of this emerging pathogen.

References

- [1] H. N. Shah, M. D. Collins, I. Olsen, B. J. Paster, and F. E. Dewhirst, "Reclassification of bacteroides levii (Holdeman, Cato, and Moore) in the genus Porphyromonas, as Porphyromonas levii comb", *int. J.syst. bacterial.*, 1995, pp. 586-588.
- [2] E. Stackebrandt and B. M. Geobel, "Taxonomic note: a place for DNA-DNA reassociation and 16S rRNA sequence analysis in the present species definition in bacteriology", *Int. J. Syst. Bacterio.*, 1994, pp. 846-849.
- [3] H. R. Jousimies-Somer, P. Summanen, S. M. Finegold, "Bacteroides levii-like organisms isolated from clinical specimens", *Clin Infect Dis.*, 1995 pp. 208-9.
- [4] A. R. Arzese, L. Tomasetig, and G. A. Botta, "Detection of tetQ and ermF antibiotic resistance genes in *Prevotella* and *Porphyromonas* isolates from clinical specimens and resident microbiota of humans", *J. Antimicrob. Chemother.*, 2000, pp. 577-582.
- [5] C. Höhne, M. Jentsch, R. Weidhase, and K.-R. Groth, "Occurrence of plasmids in black-pigmented gram-negative anaerobes. FEMS Immunol", *Med. Microbiol.*, 1993, pp.103-108.
- [6] D. Elad, O. Friedgut, N. Alpert, Y. Stram, D. Lahav, D. Tiomkin, M. Avramson, K. Grinberg, and M. Bernstein, "Bovine necrotic vulvovaginitis associated with *Porphyromonas levii*", *Emerg. Infect. Dis.*, 2004, pp. 505-507.
- [7] S. L. Hillier, M. A. Krohn, L. K. Rabe, S. J. Klebanoff, and D. A. Eschenbach, "The normal vaginal flora, H₂O₂-producing *lactobacilli*, and bacterial vaginosis in pregnant women", *Clin. Infect. Dis.*, 1993, pp. S273-S281.
- [8] D. G. Sparrow, S. Gard, A. Buret, H. Ceri, M. Olson, D. W. Morck, "Expression of tumor necrosis factor α and granulocyte-macrophage colony-stimulating factor by bovine endothelial cells in vitro", *Clin Infect Dis.*, 1997, pp. S178-9.
- [9] M. R. V. Walter, D. W. Morck, "In vitro expression of tumor necrosis factor- α , interleukin 1 β , and interleukin 8 mRNA by bovine macrophages following exposure to *Porphyromonas levii*", *Can J Vet Res.*, 2002, pp. 93-8.
- [10] D. A. Lobb, H. J. Loemann, D. G. Sparrow, D. W. Morck, "Bovine polymorphonuclear neutrophil-mediated phagocytosis and an immunoglobulin G2 protease produced by *Porphyromonas levii*", *Can J Vet Res.*, 1999, pp. 113-8.
- [11] D. Elad, O. Friedgut, N. Alpert, Y. Stram, D. Lahav, D. Tiomkin, "Bovine necrotic vulvovaginitis associated with *Porphyromonas levii*", *Emerg Infect Dis.*, 2004, pp. 505-7.
- [12] M. K. Biswas, "Bacterial vaginosis", *Clin Obstet Gynecol.*, 1993, pp. 166-76.